

# High End Implant and Ceramic Work = Natural Results

by Joseph L. Caruso, DDS, MS and Luke Kahng, CDT

The patient, a 75-year-old male, presented with non-restorable lower four anterior teeth. His partial was non-functional and his remaining maxillary teeth were few, leading him to wear a maxillary prosthetic appliance.

After analyzing the X-ray and coordinating with the clinical findings, it was determined that the mandibular anterior teeth were non-restorable. Panorex X-ray also revealed that he did have, on a two-dimensional basis, adequate bone support from the apices of the non-restorable teeth to the inferior border of his mandible in the anterior component for implants. It was also noted he had moderate atrophy of the mandibular left and right posterior ridges. The CT scan<sup>1,2</sup> of his mandible (Fig. 1) revealed that he had adequate bone thickness and bone density<sup>3</sup> apical to the infected mandibular anterior teeth for four implants.

The treatment outline<sup>4</sup> was as follows: It was decided to use an interactive CT scan utilizing SimPlant (Materialise Dental) protocol to fabricate stereo lithography stents. One of these stents had a bone reduction guide for bone reduction in the mandibular anterior area (Fig. 2). The patient was prepped with standard operating procedures on an outpatient basis. We then proceeded to extract the mandibular non-restorable anterior teeth and at that time a bone reduction guide was placed over the osseous structures. It was determined that we would perform bone contouring in the mandibular anteriors to reduce the sharp ridges that remained after the extraction. The horizontal reduction of bone resulted in a wide buccal-lingual dimension so that

circumferentially, implants would be completely encased in bone. Bone density using Hounsfield units was evaluated via SimPlant and showed that he had adequate bone density,<sup>3</sup> which consisted of D1 and D2 bone for 15mmX5mm BioHorizon implants in the mandibular anterior area. After this, the bone reduction guide was used to reduce the bone height in the mandibular anterior and eliminate the sharp ridge. Four BioHorizon implants, 5mm in diameter and 15mm in length, were strategically placed in the mandibular anterior area (Fig. 3) and temporary abutments for verification index were placed (Fig. 4). After the implants were placed using the stereo lithography guides, the ridges in the posterior quadrants bilaterally (they had a knife ridge) were reduced in order eliminate the disparity of ridge height. It was beneficial to level the bone throughout the mandibular arch by removing the very thin knife ridges in the posteriors. With the surgical reduction coping and the stereo lithography guide, the trimming of the bone of the posterior region resulted in an even osseous structure throughout the mandibular arch. The surgical protocol and implant placement resulted in excellent healing.<sup>6</sup>

Approximately four or five months after the surgery, the mandibular anterior implants were exposed and healing caps were placed. The patient has good oral hygiene and was extremely compliant. After the implants were uncovered, standard operating protocol was instituted for impression taking using an open-tray technique. Verification jigs were fabricated

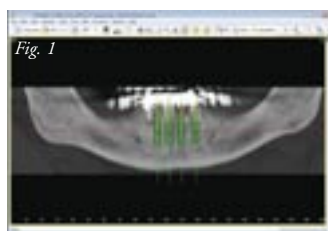


Fig. 1: The CT scan verifies the bone density and thickness.

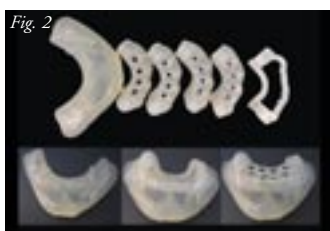

Fig. 2: Stereo lithography and bone reduction guide

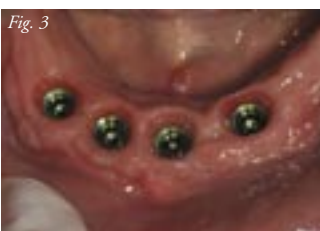

Fig. 3

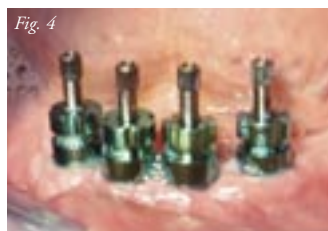

Fig. 4

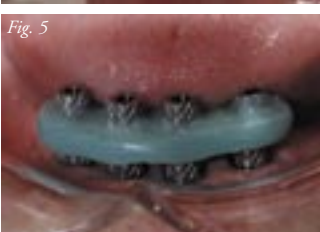

Fig. 5

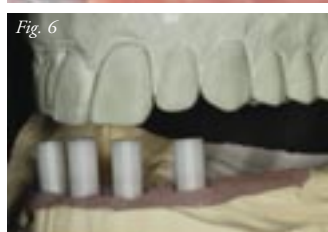


Fig. 6

Fig. 3: The implants were surgically placed.

Fig. 4: The temporary abutment verification index placed in the mouth ensures fit in the doctor's office.

Fig. 5: A verification index was used to verify implant placement.

Fig. 6: Light curing wax was applied over the lower UCLA abutments for design of the lower teeth.

and it was ascertained that he had a passive fit (Fig. 5). The protocol established was to place the patient in fixed restorations with four well-placed, well-integrated, long implants with UCLA abutments for design study, in good quality bone with the protocol of a fixed appliance (Fig. 6). The abutments were compared to the upper denture study model for proper design of the mandibular reconstruction. Maxillary reconstruction will also be planned after completion of the mandibular arch. After grinding the abutments for size check, light-curing wax was placed on top, burned out and cast, then baked at 1,550 degrees Fahrenheit (Figs. 7 & 8). Resulting frame design was completed and exhibited (Fig. 9) – ready for investing, the next completed step (Fig. 10).

After casting, the restorations were placed on the model to ensure proper fit and design (Fig. 11) and the technician performed a custom shade check (Fig. 12). Using a porcelain multi-layering technique, GC Initial MC porcelain was applied by the technician for natural, life-like crowns (Fig. 13). The porcelain had this appearance after first firing (Fig. 14) and the build-up was then checked for shade match (Fig. 15). Before firing, the completed build-up had this appearance (Fig. 16). In a side view, after immediate placement, note the detailed design of the

teeth (Fig. 17). The mesial of #27 was created to protrude slightly and the distal of #26 is purposely in slightly for a natural appearance. Likewise, the mesial of #26 is moved outward and the distal of #25 inward.

For an exact match, (Fig. 18) the gum color was created using the LSK Chairside Shade Guide system as a matching standard in order to reproduce excellent ceramic color for patient tissue. Close observation will reveal a medium pink base color, with a clear application on top and a slightly frosty layer to finalize the effect.

Regarding the shape of the gums, the technician's goal was to create a healthy appearing gingival area by following a natural convex and concave flow to the tissue. Saliva underneath the gum tissue was mimicked for a life-like gum appearance, with a whitish horizontal line in the gingival third and translucency and opal, white and clear combination in the incisal third. In the incisal edge, an orange brown color was very lightly applied to mimic exposed dentin, but not severely. Interproximally, an appropriate amount of ochre stain further mimics the age of the patient's teeth.

These modifications were applied based on the author's impression of the patient's existing dentition and his applied

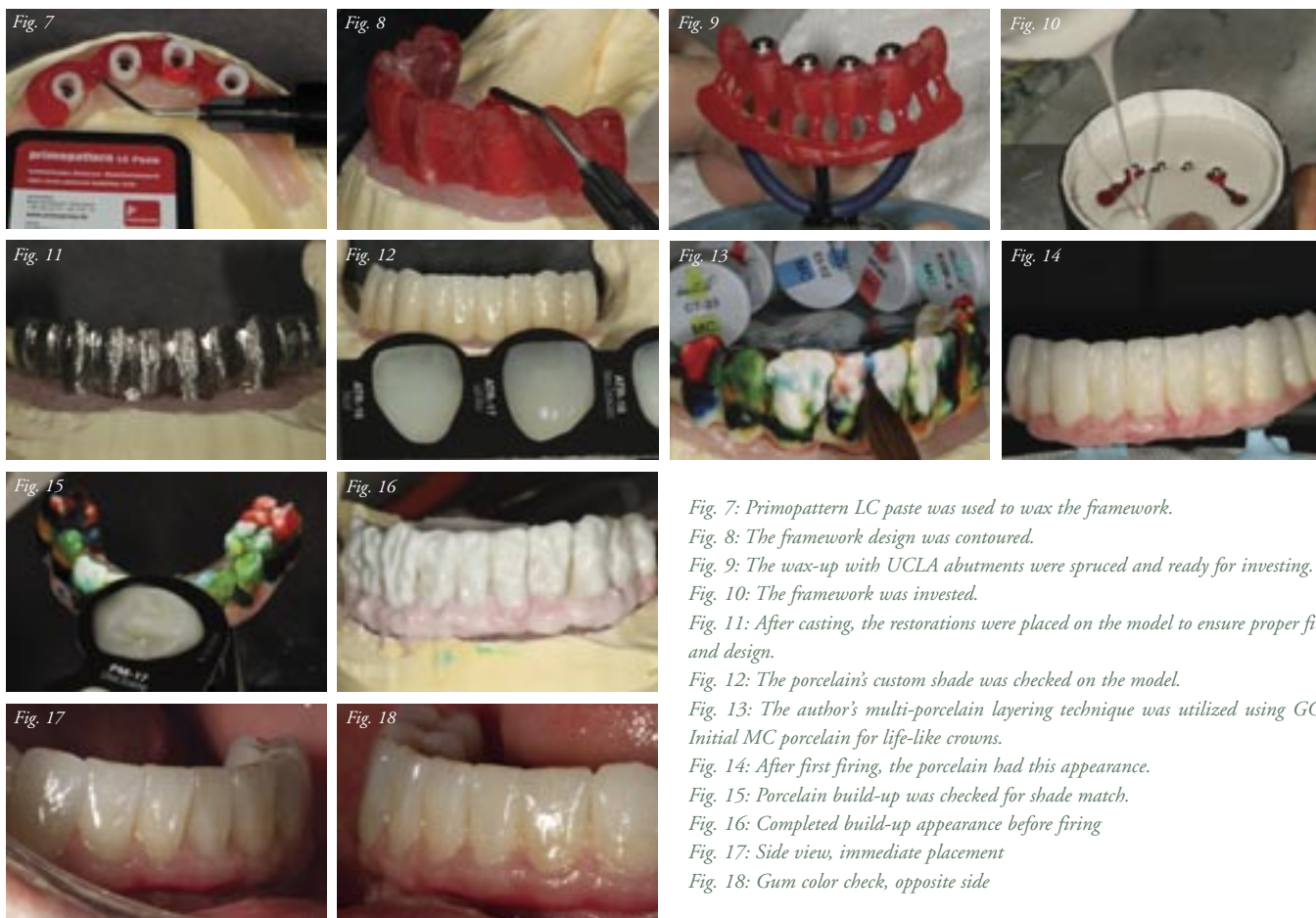

Fig. 7: Primopattern LC paste was used to wax the framework.

Fig. 8: The framework design was contoured.

Fig. 9: The wax-up with UCLA abutments were spruced and ready for investing.

Fig. 10: The framework was invested.

Fig. 11: After casting, the restorations were placed on the model to ensure proper fit and design.

Fig. 12: The porcelain's custom shade was checked on the model.

Fig. 13: The author's multi-porcelain layering technique was utilized using GC Initial MC porcelain for life-like crowns.

Fig. 14: After first firing, the porcelain had this appearance.

Fig. 15: Porcelain build-up was checked for shade match.

Fig. 16: Completed build-up appearance before firing

Fig. 17: Side view, immediate placement

Fig. 18: Gum color check, opposite side

continued on page 92

integration in order to create a vivid, life-like appearance. Understanding occlusion concepts, he knows that the mandibular needed to be built accordingly, taking into consideration the curve of Spee.

In the final full frontal view (Fig. 19), the concept of natural teeth is fully displayed. This restoration is an ideal example of a life-like case, with all the artistic skill and ceramic work coming together at the same time. These results were only possible due to perfect preparation and teamwork, all working in harmony. The proper tools – GC Initial pink porcelain for stump color and a shade guide that precisely mimics real color – contributed to the outcome, as well. These beautifully segmented teeth, flawlessly transitioned, offer a perfect solution to this patient's smile.

The various prosthetic protocols were carried out for try-ins and establishing a proper plane of occlusion and the fixed bridge was screw retained. Excellent exit of the screw holes in the prosthesis was achieved, through planning, clinician-lab communication and also with stereo lithography stents that would allow the trajectory to be at the center of the cingulum of the implants. The case was extremely successful and the patient was pleased. Oral hygiene instructions were given to the patient. It is noted that on one of the photographs, he has a maxillary temporary denture only on several teeth. Phase II of this treatment will be to remove the remaining maxillary teeth and establish the same protocol of implant placement on the maxillary arch. The patient is in treatment for the maxillary arch and the part two would be to show the completed case with the maxillary reconstruction. ■

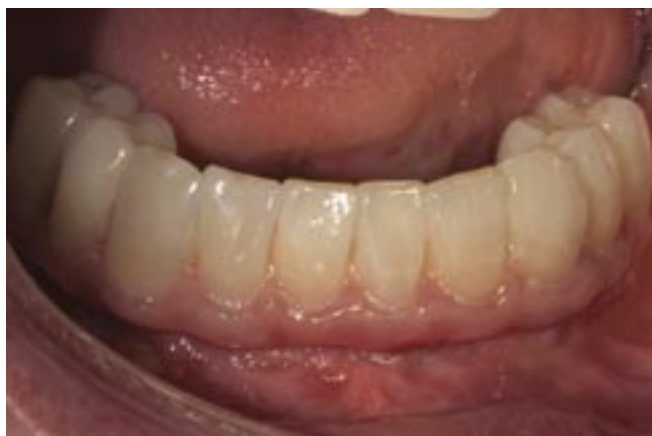

Fig. 19: Front view (final)

#### References

1. Sarment DP, Al-Shammari K, Kazor CE. (2003 Jun). Stereolithographic surgical templates for placement of dental implants in complex cases. *Int J Periodontics Restorative Dent.* 23(3):287-95.
2. Lal K, White GS, Morea DN, Wright RF (2006 Jan-Feb) Use of stereolithographic templates for surgical and prosthodontic implant planning and placement. Part I. The concept. *J Prosthodont.* 15(1):51-8.
3. Rebaudi A, Trisi P, Cella R, Cecchini G. (2010 Jan-Feb). Preoperative evaluation of bone quality and bone density using a novel CT/microCT-based hard-normal-soft classification system. *Int J Oral Maxillofac Implants.* 25(1):75-85.
4. Tischler M. 2010 Sep-Oct. Treatment planning implant dentistry: an overview for the general dentist. *Gen Dent.* 58(5):368-745.
5. Turkyilmaz, I, Turkyilmaz, TF, Tumer, C. (2007 April). Bone density assessments of oral implant sites using computerized tomography. *Journal of Oral Rehabilitation.* 34(4):267-272.
6. Abbo B, Razzoog. ME. 2007 Jul. Restoring the partially edentulous patient in the aesthetic zone: computer-guided implant surgery. *Dent Today.* 26(7):136, 138-40.

#### Author Bios

**Joseph L. Caruso, DDS, MS**, is licensed to practice dentistry in the states of Illinois and California and holds a specialty license in prosthodontics. His extensive training and experience include comprehensive and complex implant treatments along with full-mouth reconstruction emphasizing high aesthetic porcelain veneers and crowns. Dr. Caruso was awarded the Leonardo da Vinci Award for Excellence in Dentistry for 2005. He received his doctorate degree from Northwestern University's School of Dentistry and his master's degree in oral biology from Loyola University. He is active in continuing dental education and often lectures nationally and internationally on the latest diagnostic CT scans for implant and aesthetic techniques. He also participates in the testing and evaluation of advanced technological equipment and materials as they relate to modern clinical dentistry. He has been elected and is a fellow to both the American and International College of Dentists.



**Luke S. Kahng, CDT**, is the owner of LSK121 Oral Prosthetics, a dental laboratory in Naperville, Illinois. In addition to being a board member for several dental publications, he has published more than 60 articles with major dental journals. He also lectures internationally, offering hands-on seminars to dental technicians and clinicians alike.

The first edition of his highly successful Chairside Shade Selection Guide was launched in 2009, with international sales worldwide. Changes were incorporated into the second edition of the Chairside Shade Guide, launched in November 2010, with updating to include three components: posterior, anterior and rehabilitation design, specific for in-office custom shade matching techniques.

He is the author of three hardcover books, including *Anatomy from Nature*, *The Esthetic Guide Book* and *Smile Selection + CS<sup>3</sup> Clinical Cases*. Visit [www.lsk121.com](http://www.lsk121.com) for more information.

